

## Open Surgical Exposure of Labially Impacted Maxillary Canine: Periodontal Aspect of 2 Cases

Dr. Swetha Subramanian<sup>1</sup>, Dr. Sangamithra Sidharthan<sup>2</sup>,  
Dr. Sivaram Gopalakrishnan<sup>3</sup>

<sup>1</sup>Consultant Periodontist, Mumbai

<sup>2</sup>Consultant Periodontist, Chennai

<sup>3</sup>Professor, Dept. of Periodontics, Ragas Dental College and Hospital, Chennai

---

**Abstract:** Impaction of maxillary canines is a frequently encountered clinical problem in orthodontic therapy. When a preventive approach fails, treatment involves surgical exposure of the impacted tooth, followed by orthodontic traction to guide and align it into the dental arch. The primary goal of surgical phase is to provide the means for correct position of orthodontic anchorage. Additionally, the technique used must ensure favorable tissue anatomy that will permit long-term maintenance of periodontal health. This report describes the periodontal perspective in management of two cases with labially impacted maxillary canines. Also, the importance of a multidisciplinary approach to achieve optimal esthetic and functional outcomes has been highlighted.

**Key words:** Impacted maxillary canines, apically repositioned flap, multidisciplinary approach

---

### I. Introduction

Maxillary canines, after the third molars, are the most commonly impacted teeth. Approximately one-third of impacted maxillary canines are located labially with 8% patients having bilateral impactions [1]. The preventive approach to this condition involves early diagnosis and extraction of primary canines in order to achieve self-correction of the improper eruption of permanent canines. However, in most clinical situations surgical exposure of the impacted permanent tooth, followed by orthodontic traction to guide and align it into the dental arch is indicated.

The primary goal of surgical phase is not only to provide the means for correct position of orthodontic anchorage, but also to procure the tooth with favorable tissue anatomy that will permit the long-term maintenance of periodontal health. Studies have demonstrated that impacted teeth on the vestibular side of the loose alveolar mucosa bear significant recession and gingivitis when an approach that does not preserve the keratinized gum around the neck of the tooth is employed [2, 3].

Kokich et al. (2004) reported three methods for uncovering a labially impacted maxillary canine depending on the canine cuspal position relative to the mucogingival junction (MGJ) [4]:

- Gingivectomy: When the canine cusp is coronal to the MGJ,
- Apically positioned flap: Canine cusp is apical to the MGJ, and
- Closed eruption technique: Canine cusp is significantly apical to the MGJ/ tooth is very high within the buccal sulcus.

The following report describes the periodontal perspective in surgical exposure of labially impacted maxillary canines in two cases undergoing orthodontic treatment.

### II. Case Reports

#### Case 1:

A 13 year old male patient with bilaterally impacted maxillary canines, under active orthodontic treatment, was referred from the Dept. of Orthodontics to the Dept. of Periodontics, Ragas Dental College and Hospital, Chennai. Clinical and radiological evaluation revealed superficial soft tissue impaction of bilateral maxillary canines [Fig 1a, 1b]. The gingiva and periodontal health surrounding the impacted teeth were normal, with the exception of thin labial keratinized tissue. Apically repositioned flap was the treatment of choice for crown exposure and to increase the band of keratinized tissue.

#### Surgical Procedure:

Two parallel/slightly apically diverging vertical incisions were made mesial and distal to the canines bilaterally, preserving the papillae of the adjacent teeth. A split thickness flap was elevated along the cusp of the unerupted canines. Finally, the flap folded to an apical position, was sutured with 4-0 silk to the alveolar mucosa, leaving more than half of the crown exposed [Fig. 1c, 1d]. Orthodontic brackets were placed 7 days

following the surgical procedure. The canines were aligned in their correct position in the arch 1 month following active orthodontic therapy [Fig. 1e, 1f].

#### **Case 2:**

A 23 year old male patient with multiple impacted teeth, under orthodontic treatment, was referred to the Dept. of Periodontics, Ragas Dental College and Hospital, Chennai for re-treatment of impacted right maxillary canine and premolars. The patient had undergone closed eruption technique before one year during which orthodontic buttons were placed and a ligature wire was tied to the button. However, the tooth failed to erupt and was suspected to be ankylosed. CBCT evaluation did not reveal ankylosis or resorption of the root. The patient was now referred for open surgical exposure of the crown to facilitate placement of orthodontic bracket for tooth movement.

Clinical evaluation revealed that the position of the right canine was high in the region of the mucobuccal fold, the cusp being at the level of the middle third of the root of lateral incisor [Fig. 2a]. The decision to perform apically repositioned flap was made considering the following reasons:

- Previous surgical procedure and position of the tooth in the arch,
- Presence of thick but unattached gingiva,

#### **Surgical Procedure:**

A full thickness flap was elevated to uncover the crown followed by split thickness flap to the extent possible to facilitate flap repositioning. Vertical releasing incisions were given on mesial and distal aspects and osteoplasty was done around the tooth [Fig. 2b]. Following debridement, flap was sutured in an apical position with 3-0 silk sutures. Orthodontic brackets were placed after 7 days and gradual traction was applied over a period of 2-3 months [Fig. 2c]. Further periodontal treatment in the form of debridement (closed or open) and gingivoplasty after completion of orthodontic treatment was indicated [Fig. 2d]

### **III. Discussion**

Orthodontic treatment is associated with soft and hard tissue changes, thus creation and maintenance of gingival and periodontal health is paramount to ensure optimal results. Although no specific dimensions of keratinized tissue have been indicated for maintenance of periodontal health, in orthodontic cases presence of keratinized tissue is important to prevent formation of periodontal defects [5].

Classically, three fundamental principles are considered when treating impacted teeth: the surgical approach, the type of fixation that is adhered to the tooth for its posterior traction and the orthodontic movements that have to be applied in order to position the tooth in the dental arch [6]. From a periodontal perspective, the appropriate surgical technique should allow the orthodontist to apply measured forces in a favorable direction for efficient correction of the impaction and for avoidance of damage to adjoining soft tissues and teeth [7].

The present study investigated the long-term results of the successful orthodontic resolution of the impaction of maxillary canines in which an open-surgical exposure technique had been used. The main clinical advantage of this technique, other than its simplicity, is that the crown remains in full view at the end of surgery, and bonding of an attachment may be subsequently performed in the orthodontic clinic in a bloodless environment and without the stress involved during the surgical procedure. This report describes 2 cases of maxillary canine impaction treated with apically repositioned flap technique. The apically repositioned flap allows creation of keratinized gingiva postoperatively, thereby facilitating maintenance of the mucogingival complex. In the first case, despite the superficial soft tissue impaction of the canines, gingivectomy was not indicated as it would have resulted in stripping-off of the attached gingiva. Optimal esthetic and functional post-operative results were achieved following apically repositioned flap technique.

The second case describes open surgical re-treatment for exposure of the impacted canine. The position of the impacted tooth warranted the use of closed eruption technique in order to provide adequate attached gingival support. However, the disadvantages of this technique are diminished control of tooth movement, adverse periodontal responses and longer treatment duration [8, 9]. Thus, the apically repositioned flap was the treatment of choice, as in Case I to prevent further damage to the mucogingival complex.

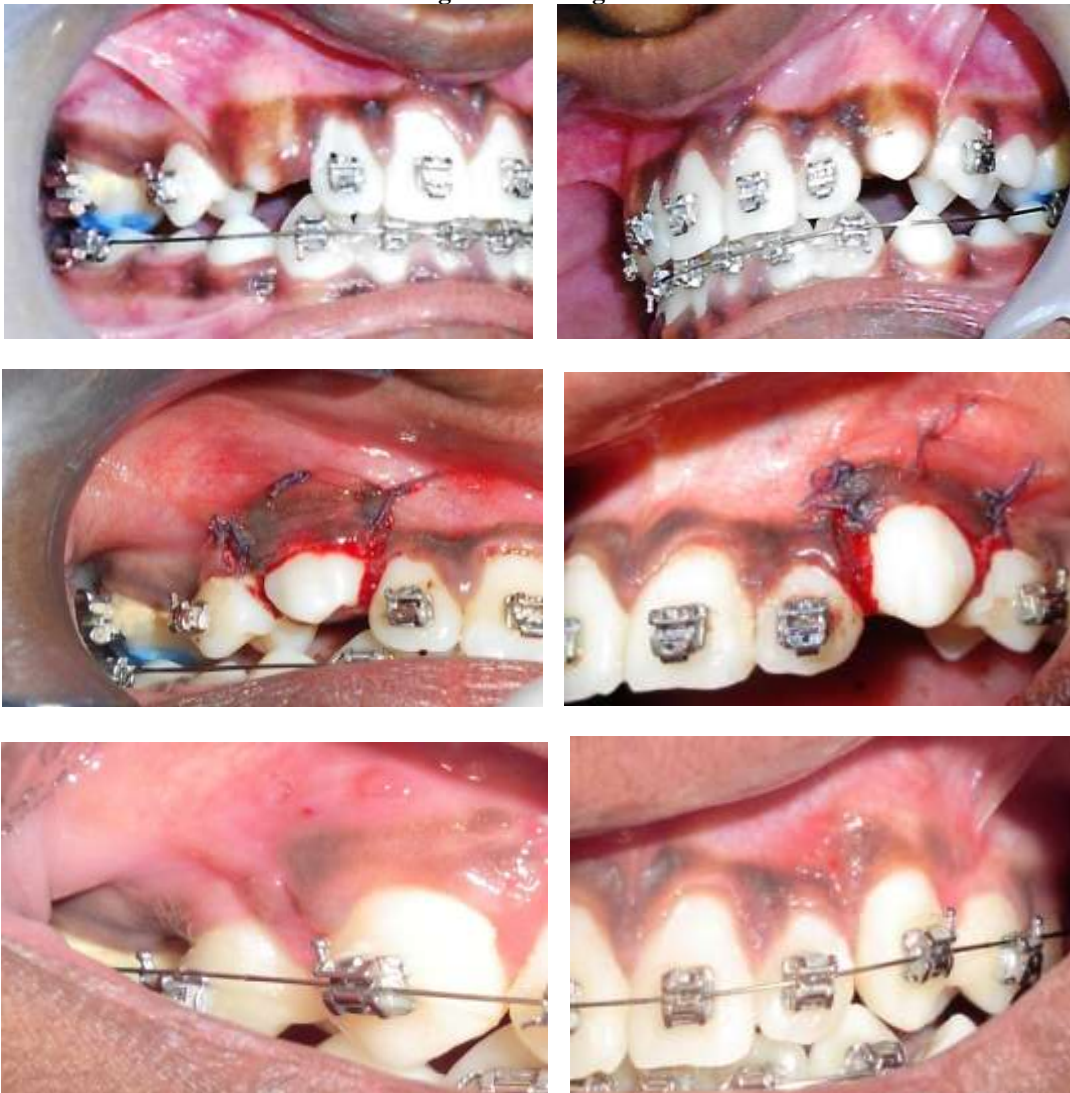Canine impactions have been suggested to be associated with the following sequelae: Shafer *et al.* (1963) [10]:

- Migration of the neighboring teeth and loss of arch length,
- Internal resorption,
- Dentigerous cyst formation,
- External root resorption of the impacted tooth, as well as the neighboring teeth,
- Infection particularly with partial eruption, and
- Referred pain and combinations of the above sequelae.

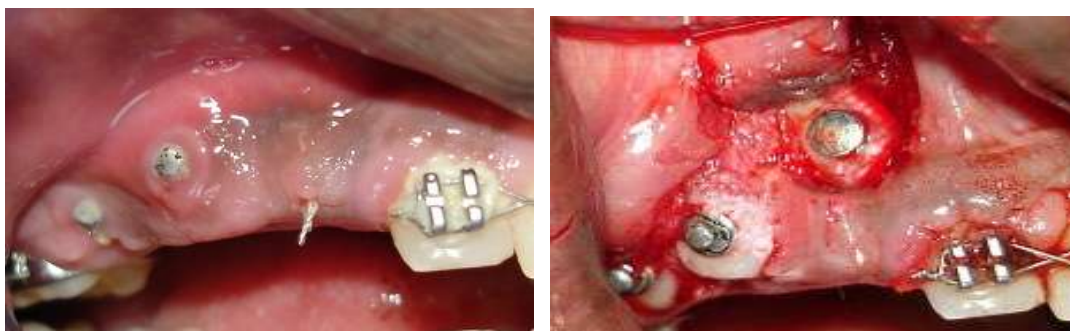Thus, accurate localization, selection of appropriate surgical approach, conservative management of the soft tissues, rigid anchorage unit, and the direction of the orthodontic traction are the important factors for the successful management of impacted canines.

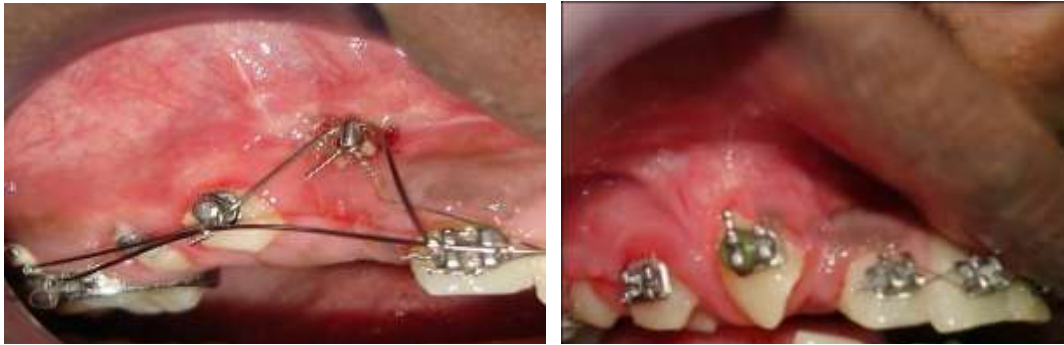
A multidisciplinary approach is therefore essential for treating impacted teeth in order to achieve optimal esthetic and functional outcomes.

**Figures And Legends**



**Figures 1a-f:** Case 1: (a), (b) Pre-operative; (c), (d) Apically repositioned flap irt 13, 23; (e), (f) Post-operative: Canines aligned in the arch.





**Figures 2a-d:** Case 2: (a) Pre-operative; (b) Apically repositioned flap with osteoplasty around 13, Gingivectomy irt 14,15; (c) Orthodontic traction; (d) Post-operative: Note the inflamed gingiva and uneven margins—Aesthetic recontouring advised after orthodontic therapy

### References

- [1]. Bishara SE. Impacted maxillary canines: A review. *Am J OrthodDentofacial Orthop.*1992; 101:159–71.
- [2]. Tegsjö U, Valerius-Olsson H, Andersson L. Periodontal conditions following surgical exposure of unerupted maxillary canines-a long term follow-up study of two surgical techniques. *Swed Dent J.* 1984; 8:257-63.
- [3]. Wisth PJ, Norderval K, Boe OE. Periodontal status of orthodontically treated impacted maxillary canines. *Angle Orthod.* 1976; 46:69-76.
- [4]. Kokich VG. Surgical and orthodontic management of impacted maxillary canines.*Am J OrthodDentofacialOrthop.* 2004; 126:278–83.
- [5]. WennstromJ,Lindhe J. Role of attached gingiva for maintenance of periodontal health. Healing following excisional and grafting procedures in dogs.*JClinPeriodontol.* 1983; 10(2):206-21.
- [6]. Proffitt WR. *Contemporary Orthodontics*, St. Louis: CV Mosby, 1986, pp 408-11.
- [7]. Patel S. Alignment of impacted canines with cantilevers and box loops. *J Clin Orthod.*1999; 33:82–5.
- [8]. Bishara SE. Clinical Management of Impacted Maxillary Canines. *Seminars in Orthodontics* 1998; 4(2):87-98.
- [9]. Vanarsdall RL Jr. Efficient Management of Unerupted Teeth: A Time-Tested Treatment Modality. *Seminars in Orthodontics* 2010; 16(3):212-221.
- [10]. Shafer WG, Hine MK, Levy BM, editors. *A textbook of oral pathology*, 2nd ed, WB Saunders: Philadelphia, 1963; pp. 2–75.